

Evaluation of Adipose-Derived Stromal Vascular Fraction or Bone Marrow-Derived Mesenchymal Stem Cells for Treatment of Osteoarthritis

David D. Frisbie, John D. Kisiday, Chris E. Kawcak, Natasha M. Werpy, C. Wayne McIlwraith

Equine Orthopaedic Research Center, Department of Clinical Sciences, Colorado State University, 300 West Drake Road, Fort Collins, Colorado 80523

Received 19 December 2008; accepted 7 May 2009

Published online 18 June 2009 in Wiley InterScience (www.interscience.wiley.com). DOI 10.1002/jor.20933

ABSTRACT: The purpose of this study was the assessment of clinical, biochemical, and histologic effects of intraarticular administered adipose-derived stromal vascular fraction or bone marrow-derived mesenchymal stem cells for treatment of osteoarthritis. Osteoarthritis was induced arthroscopically in the middle carpal joint of all horses, the contralateral joint being sham-operated. All horses received treatment on Day 14. Eight horses received placebo treatment and eight horses received adipose-derived stromal vascular fraction in their osteoarthritis-affected joint. The final eight horses were treated the in osteoarthritis-affected joint with bone marrow-derived mesenchymal stem cells. Evaluations included clinical, radiographic, synovial fluid analysis, gross, histologic, histochemical, and biochemical evaluations. No adverse treatment-related events were observed. The model induced a significant change in all but two parameters, no significant treatment effects were demonstrated, with the exception of improvement in synovial fluid effusion PGE2 levels with bone marrow-derived mesenchymal stem cells when compared to placebo. A greater improvement was seen with bone marrow-derived mesenchymal stem cells when compared to adipose-derived stromal vascular fraction and placebo treatment. Overall, the findings of this study were not significant enough to recommend the use of stem cells for the treatment of osteoarthritis represented in this model. © Orthopaedic Research Society. Published by Wiley Periodicals, Inc. *J Orthop Res* 27:1675–1680, 2009

Keywords: bone marrow-derived mesenchymal stem cells; stromal vascular fraction; osteoarthritis; in vivo model; equine

Joint disease and specifically osteoarthritis (OA) is one of the most prevalent and debilitating diseases clinically affecting both humans¹ and horses.^{2,3} Furthermore, similarities in joint disease between the two species have allowed translational research to be conducted in the horse.⁴ Specifically, models of cartilage healing and OA have been developed in the horse allowing controlled studies to be performed on therapeutic interventions that have clinical relevance to both human and equine patients.^{4,5} To date, 12 other studies assessing clinically relevant therapeutic interventions have been published using a randomized blinded placebo controlled model of OA in the horse. Currently, no one therapeutic intervention for OA in any species has proven effective at long-term symptom-modifying or disease-modifying effects.⁶ Recently, anecdotal reports have described full return to athletic function in 70% of equine OA patients treated using intraarticular (IA) administration of adipose-derived stromal vascular fraction (ADSVF) (R. Harman et al., 2007, personal communication, <http://www.vet-stem.com>). Also, an uncontrolled multicenter equine clinical trial using IA treatment of bone marrow-derived mesenchymal stem cells (BMDMSC) for inoperable meniscal lesions has shown early promise.⁷ These results, coupled with in vivo studies that have shown significant disease-modifying effects using BMDMSC for the treatment of joint instability⁸ and collagen-induced arthritis,⁹ have fueled new enthusiasm for mesenchymal stem cells (MSC) as a novel treatment for OA. To date, one controlled clinical

study¹⁰ has been published limiting the overall translational information. The goal of this study was to assess BMDMSC and ADSVF ability to decrease the progression of OA without joint instability, as well as compare ADSVF and BMDMSC.

METHODS

Experimental Design and Induction of Osteoarthritis

Twenty-four skeletally mature 2–5-year-old horses, free of musculoskeletal abnormalities [pain, range of motion, and joint effusion in the carpal joints (front knee)], were utilized in the study. Horses were randomly assigned to one of three treatments groups: ADSVF ($N=8$), BMDMSC ($N=8$), or placebo (PCB) ($N=8$). All evaluators were unaware of treatment assignment.

As previously described,^{5,11} on Day 0, following anesthesia and routine preparation for surgery, each horse underwent bilateral arthroscopic surgery of the middle carpal joints to ensure that there were no preexisting abnormalities. During this procedure, an 8-mm osteochondral fragment was created in one randomly selected middle carpal joint. The fragment was allowed to remain adhered to the joint capsule proximally. A motorized arthroburr was used to debride the exposed subchondral bone between the fragment and parent bone creating a 15-mm defect. The debris was not actively flushed from the joint, thereby participating in the induction of osteoarthritis. This joint was designated as the OA-affected joint; the sham-operated contralateral joint was used as the control joint. The arthroscopic portals were closed routinely. Horses assigned to the BMDMSC group also had a 40–50 mL aspirate of bone marrow suspended in 3,000 units of sodium heparin which was aseptically harvested from the sternum. Postoperative care followed routine clinical standards.

Routine harvest of adipose tissue occurred for the ADSVF horses (Vet-StemTM, Poway, CA). Briefly, using systemic sedation, routine surgical preparation, and local anesthetic, a

Correspondence to: David D. Frisbie (T: 970-297-4555; F: 970-297-4138; E-mail: dfrisbie@colostate.edu)

© 2009 Orthopaedic Research Society. Published by Wiley Periodicals, Inc.

6-cm skin incision parallel to the spine at the level of the tail head was made and 10–20 g of adipose tissue was harvested. A routine closure of the incision was performed. The adipose was shipped to the manufacturer, where the tissue was washed with phosphate buffered saline (PBS), minced, then digested in low glucose Dulbecco's modified Eagle's medium (DMEM) containing 10% fetal bovine serum (FBS) and 0.1% collagenase for 3–4 h with agitation. Nucleated adipose cells were pelleted, washed, and resuspended in PBS for injection; finally, the cells were shipped to CSU. The total nucleated cell count normalized to the lowest quantity obtained, which was 16.3 million nucleated cells.

BMDMSC Culture Technique

Marrow aspirates were washed in PBS and then mixed with 0.8% ammonium chloride. The cell pellet was rinsed with PBS, resuspended in low glucose DMEM containing 10% FBS, and seeded in flasks at a concentration of 0.66×10^6 nucleated cells/cm². Confluent BMDMSC colonies developed over 10–12 days, at which point the cells were reseeded and expanded in growth medium containing 1 ng/mL FGF-2. BMDMSC cultures were passaged at a split ratio of 1:3 twice prior to treatment.¹²

Exercise

Horses were housed in stalls (3.65 × 3.65 m each). Beginning on Day 15, horses were exercised on a high-speed treadmill 5 days each week throughout the study. Horses were trotted (16–19 km/h) for 2 min, galloped (approximately 32 km/h) for 2 min, and trotted again (16–19 km/h) for 2 min daily to simulate the strenuous exercise of race training.

Treatment Groups

All horses were treated on Day 14 postsurgery. PCB horses received 2 mL 0.9% NaCl in their OA-affected joint. The ADSVF horses received 16.3 million total nucleated cells suspended in 2 mL of 0.9% buffered NaCl in their OA-affected joint. OA affected joints of BMDMSC horses were treated with a mean of 10.5 million (SEM = 1.1 million cells, range of 5.6–15 million cells) culture expanded BMDMSC suspended in 2 mL 0.9% buffered NaCl.

Assessment of Clinical Outcomes

Clinical examinations of both forelimbs were performed every 2 weeks throughout the study period. Pain was graded on a standardized 0–5 scale.¹³ All other clinical, histologic, and histochemical outcomes were graded on a 0–4 scale (0 represented normal, 4 represented severe change). Joint effusion was measured as an indication of inflammation, and joint range of motion was measured through carpal flexion.

Bilateral radiographic carpal evaluation occurred on Day –7, Day 14, and Day 70. Images were evaluated for bony proliferation at the joint capsule attachment, subchondral bone lysis, and osteophytes.

Synovial Fluid

Synovial fluid was collected weekly from both middle carpal joints. Samples were assessed for total protein concentration using a refractometer, cytologic evaluation, total white blood cell (WBC) count, or stored at –80°C for biochemical protein analysis.

A modified 1,9-dimethyl-methylene blue dye-binding assay was used to determine glycosaminoglycan (GAG) concentration.¹⁴ Synovial fluid concentration of prostaglandin E2 (PGE2) was also assessed (PGE2 Kit, Assay Designs, Ann Arbor, MI).

Tumor Necrosis Factor- α (TNF- α) concentrations in serum and synovial fluid samples were determined using a commercially available indirect ELISA kit (Endogen, Rockford, IL) that has been previously validated in equine samples.^{15,16} The assay was used according to manufacturer's instructions, and absorbance was measured at A450. The upper and lower detection limits were 5,702.196 and 2.1 pg/mL, respectively.

Gross Pathologic Observations of Joints

Following euthanasia on Day 70 with an overdose of pentobarbital, both middle carpal joints were specifically examined for degree and location of articular cartilage fibrillation or erosion, as well as synovial membrane hemorrhage.

Histologic Examinations

Synovial membrane was harvested and placed in neutral-buffered 10% formalin, embedded in paraffin, 5- μ m sections created and stained with hematoxylin and eosin (H&E). Sections were assessed for cellular infiltration, synovial intimal hyperplasia, subintimal edema, subintimal fibrosis, and subintimal vascularity.¹¹

Articular cartilage pieces (5 mm²) were obtained from each joint; samples were fixed neutral-buffered 10% formalin embedded in paraffin, 5- μ m sections created and stained with both H&E or Safranin O, fast green (SOFG). H&E sections were evaluated for articular cartilage fibrillation, chondrocyte necrosis, chondrone formation, and focal cell loss.¹¹ SOFG sections were evaluated for intensity of staining in each chondrocyte layer.¹¹

Articular Cartilage Matrix Evaluation

Articular cartilage proteoglycan content was estimated by use of a 1,9-dimethyl-methylene blue technique¹⁴ on samples obtained from each joint that were stored at –80°C. For analysis of cartilage matrix metabolism, articular cartilage samples were aseptically collected, and radiolabeled SO₄ (³⁵SO₄) incorporation was measured by use of previously reported methods.¹¹

Statistical Analysis

Data were evaluated using an ANOVA framework with PROC GLIMMIX of SAS¹⁷ with the horse as a random variable. The ANOVA tables were used to determine significant main effect and interactions between main effect variables. When individual comparisons were made, a least square means was utilized and a *p*-value less than or equal to 0.05 was considered significant. Data was tested for normality using residual plots and, when required, natural log transformations performed to ensure normality. When transformation was performed, data is presented in natural log.

RESULTS

Clinical Outcomes

Musculoskeletal

All horses showed a significant pain increase (*p* < 0.0001) in the OA-affected [2.33 ± 0.06 (mean ± SE)] limb when compared to the sham-operated limb (0.00 ± 0.06) on Day 14 (prior to treatment). Change in pain values were calculated using Day 14 (the last pretreatment evaluation) as the post-osteoarthritis but pretreatment baseline (a positive change score indicates

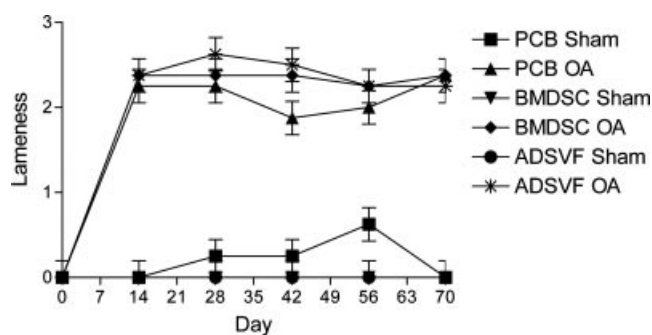


Figure 1. Raw lameness scores (mean ± SEM) plotted by time for each treatment group as well as for the osteoarthritis-affected and Sham limbs. No significant differences were noted in any comparison except for an increase in osteoarthritis joints postsurgery.

improvement). There was no significant improvement in pain score with respect to treatment (Fig. 1).

Flexion

All horses showed a significant increase ($p < 0.0001$) in flexion score (representing a decreased range of motion) in the OA-affected (2.50 ± 0.08) limb when compared to the sham-operated limb (0.08 ± 0.08) for Day 14. Change in flexion was calculated using Day 14 as the post-osteoarthritis but pretreatment baseline, and significant improvements ($p = 0.0013$) based on treatment group and joint were seen. Improvement in the OA-affected limbs that received PCB and BMDMSC treatments were seen when compared to ADSVF (Fig. 2).

Joint Effusion

All horses showed a significant increase ($p < 0.0001$) in effusion score in the OA-affected (2.25 ± 0.08) joints compared to the sham-operated joints (0.13 ± 0.08) for Day 14. Change in joint effusion was calculated using Day 14 as the post-osteoarthritis but pretreatment baseline; no significant differences were observed in any comparisons.

Radiographic Evaluation

A significant increase in radiographic joint pathology was induced following induction of OA as demonstrated

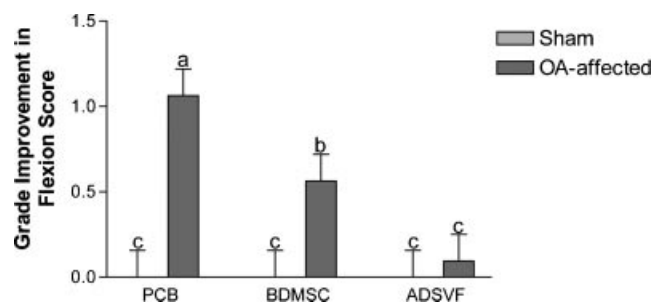


Figure 2. The grade improvement in flexion score (mean ± SEM) plotted by treatment group. Different letters indicate a significant difference between bars.

by a significantly ($p < 0.0001$) higher cumulative radiographic score in the OA-affected (1.19 ± 0.12) compared to the sham-operated (0.06 ± 0.12) joints. No significant treatment effects were detectable.

Synovial Fluid

Routine synovial fluid analysis indicated, as expected, the total protein concentration increased significantly ($p < 0.0001$) with induction of OA throughout the study period when sham-operated (2.08 ± 0.09) were compared to OA-affected joints (2.70 ± 0.09). Synovial fluid WBC counts were significantly increased ($p < 0.0001$) by the induction of OA, with OA-affected joints having a higher WBC count compared to sham-operated joints (245 ± 32 vs. 169 ± 32 cell/dL, respectively). There were no significant treatment effects seen in synovial total protein or WBC counts. Based on the cytology of the synovial fluid WBCs, there were significantly ($p = 0.0070$) less lymphocytes in the ADSVF OA-affected joints compared to all other joints (Table 1).

Synovial GAG concentrations were significantly ($p < 0.0001$) increased with induction of OA; OA-affected joints (4.45 ± 0.02 Ln μg GAG/mL) had an increase GAG concentration when compared to sham-operated joints pretreatment (4.33 ± 0.02 Ln μg GAG/mL). No significant treatment effects were seen in synovial fluid GAG concentration.

Synovial fluid PGE2 concentrations were significantly ($p < 0.0001$) increased with induction of OA (4.24 ± 0.09 Ln pg/mL), compared to the sham-operated joints (3.23 ± 0.09 Ln pg/mL). A significant ($p = 0.0423$) decrease in synovial PGE2 concentration was seen in BMDMSC compared to PCB treatment horses starting on Day 35 (Fig. 3a). This affect was independent of joint, although synovial fluid from OA-affected joints demonstrated a more pronounced difference (Fig. 3b). Synovial fluid TNF concentrations were significantly ($p = 0.0005$) increased with induction of OA (2.18 ± 0.3 Ln pg/mL), compared to sham-operated joints (1.73 ± 0.29 Ln pg/mL). The only significant ($p = 0.0194$) treatment difference was higher TNF concentrations in OA-affected (2.69 ± 0.52 Ln pg/mL) compared to sham-operated (1.72 ± 0.51 Ln pg/mL) joints of ADSVF-treated horses.

Table 1. Cytology of the Synovial Fluid White Blood Cells, Specifically the Percentage of White Blood Cells that Were Lymphocytes*

Treatment Group	No OA	OA
Placebo	14.58 ^a ± 1.19	13.81 ^a ± 1.19
BMDMSC	14.80 ^a ± 1.19	14.56 ^a ± 1.19
ADSVF	13.50 ^a ± 1.19	9.38 ^b ± 1.19

OA, osteoarthritis; BMDMSC, bone marrow-derived mesenchymal stem cells; ADSVF, adipose-derived stromal vascular fraction. *Significantly ($p = 0.0070$) less lymphocytes were noted in the adipose-derived stromal vascular fraction osteoarthritis-affected joint compared to all other joints (different letters indicate a significant difference).

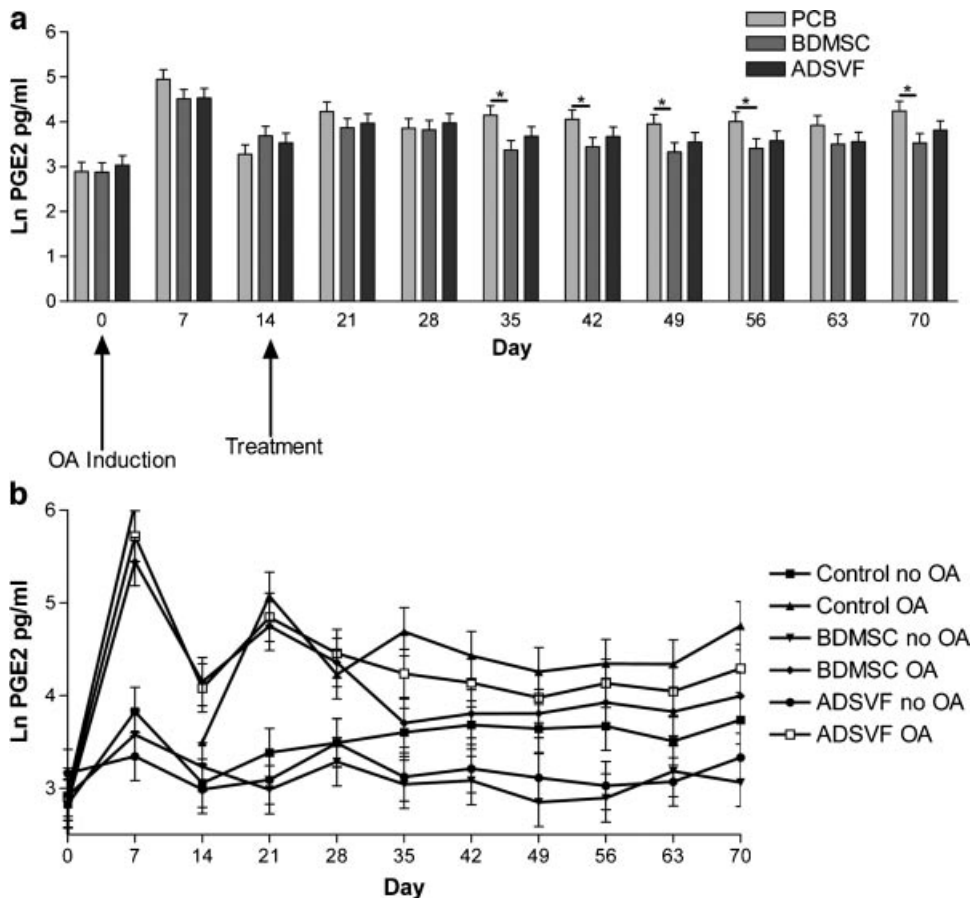


Figure 3. (a) Natural log of PGE2 concentration plotted by Day for each treatment group (average of both the osteoarthritis-affected and Sham joints). An asterisk represents a significant difference between the comparison. (b) Natural log of PGE2 concentration plotted by Day for each treatment group (for both the osteoarthritis-affected and Sham joints).

Gross Pathologic Observations of Joints

At necropsy, hemorrhage within the synovial membrane was significantly ($p=0.0002$) increased in OA-affected (1.79 ± 0.13) compared with sham-operated (1.13 ± 0.13) joints. Similarly, articular cartilage total erosion scores were significantly ($p < 0.0001$) increased in OA-affected joints (2.42 ± 0.14) compared with sham-operated joints (1.38 ± 0.14). No significant treatment effects were seen for any of the gross pathologic observations.

Histologic Examinations

Synovial Membrane H&E

There was a significant ($p=0.0061$) increase in the cumulative pathology score for the synovial membrane in OA-affected (5.17 ± 0.45) when compared to sham-operated (3.25 ± 0.45) joints. No significant treatment effects were demonstrated.

Articular Cartilage H&E

Cartilage stained with H&E showed a significant ($p < 0.0131$) increase in the modified Mankin score (cumulative score of all four outcome parameters) when OA-affected (3.43 ± 0.53) were compared with sham-operated (1.63 ± 0.53) joints based on location. No significant treatment effects were observed based on the total modified Mankin score or individual outcome parameters.

Articular Cartilage SOFG

Evaluation of articular cartilage for SOFG staining did not demonstrate a significant difference when OA-affected (8.35 ± 0.42) were compared to sham-operated (8.28 ± 0.42) joints or treatment comparisons.

Articular Cartilage Matrix Evaluation

No significant difference was noted with the cartilage GAG content or GAG synthesis with respect to induction of disease or treatment group.

DISCUSSION

The current study used a model of OA that effectively induced significant clinical, gross, histologic, and biochemical changes indicative of OA. The authors believe this is the first controlled study to assess clinical musculoskeletal pain following the treatment of OA with MSCs. While all of the clinical parameters were significantly increased following the induction of OA, improvements were not demonstrated with ADSVF or BMDMSC treatment. This is in contrast to anecdotal reports presented by Vet StemTM following the clinical use of ADSVF (R Harman et al., 2007, personal communication, <http://www.vet-stem.com>). The authors assume the uncontrolled nature of case selection, variability in clinical disease progression, as well as lack of treatment uniformity in the Vet-StemTM cases

are most likely responsible for the disparity. In fact, more improvement in range of motion (measured by joint flexion) was gained with placebo treatment than with either ADSVF or BMDMSC, with the least significant response being seen in the ADSVF-treated horses. It is difficult to explain these findings, given that other outcome parameters that typically accompany change in joint flexion (significant change in synovial membrane pathology and radiographic pathology at joint capsule margin) were not seen in this study.

Induction of OA significantly increased synovial fluid PGE2 concentrations. This finding would be expected with joint disease as a marker of inflammation^{5,18} and can be driven by a host of proinflammatory cytokines. While a decrease in synovial fluid PGE2 was seen with ADSVF treatment, this difference was not statistically significant. Conversely, treatment with BMDMSC not only significantly decreased synovial fluid PGE2 levels in the OA-affected limb, but also showed a systemic effect through significantly decreasing the PGE2 concentration in the sham-operated limb as well. The reduction of PGE2 represents a decrease in overall joint inflammation and has historically been positively correlated with a decrease in pain,^{18–21} although no significant reduction in pain was observed as a result of BMDMSC or ADSVF treatment. Previously in this model, when a significant reduction of PGE2 has been noted, a decrease in clinical pain has also been observed as was the case following IA administration of corticosteroids.^{22,23} Treatment using interleukin-1 receptor antagonist^{11,24} demonstrated both symptom- and disease-modifying effects without reduction of synovial PGE2 levels. Thus, PGE2 reduction is not a prerequisite for symptom-modifying effects. While a decrease of TNF- α has been shown to occur following peritoneal treatment with allogeneic BMDMSC in mice with collagen-induced arthritis,⁹ leading to a decrease in inflammation measured through paw size and discoloration, TNF- α was not decreased in the current study. In fact, treatment with ADSVF increased synovial fluid TNF- α .

Murphy et al. observed a decrease in progression of OA following treatment with autologous BMDMSC and hyaluronic acid using a medial meniscectomy and anterior cruciate deficient model in the goat.⁸ This study also demonstrated a neomeniscal tissue formation associated with animals showing a decreased OA. Barry postulated that the increase in stability afforded from the neomeniscal tissue was most likely responsible for the decreased progression of OA,²⁵ a fact that is supported by the lack of decreased OA progression in the current OA model which does not have an instability component. It should be noted that the current study did not use the addition of hyaluronic acid with the MSC administration and, thus, may have decreased the resident time of the cells in the joint space. It is of interest to the authors that a short-term follow-up (6–18 months) on equine patients suffering from meniscal disease, and treated with BMDMSC plus hyaluronic acid, did show a better than expected return to full athletic work (67%) following

previous failure of medical treatment, as well as a poor prognosis following diagnostic arthroscopy.⁷

A secondary goal of the current study was to compare treatment effects of ADSVF and BMDMSC. Because only significant improvement in synovial PGE2 concentrations could be demonstrated with BMDMSC, this comparison is somewhat limited; finding a greater magnitude of an effect with bone marrow- versus adipose-derived cells has also been seen with multiple other studies involving musculoskeletal tissues and is, thus, not that surprising.^{26–29}

In summary, no adverse effects were noted with BMDMSC administration. The administration of ADSVF was associated with increased synovial fluid TNF- α concentration, which is worrisome. The only significant beneficial effect was noted in synovial PGE2 level reduction following BMDMSC treatment. Overall, this modest improvement based on the number of other outcome parameters dampens the enthusiasm of the authors' use of unmodified MSC in the treatment of OA. Further modification using gene therapy or selection of subpopulations of MSC needs to be explored for the treatment of OA.

ACKNOWLEDGMENTS

Vet-Stem™ Poway, CA provided partial funding for this study. None of the authors' professional or financial affiliations have biased this presentation. The authors thank all of the staff and volunteers at the Equine Orthopaedic Research Center at Colorado State University for their help and participation in this study.

REFERENCES

1. Lawrence R, Helmick C, Arnett F, et al. 1998. Estimates of the prevalence of arthritis and selected musculoskeletal disorders in the United States. *Arthritis Rheum* 41:778–779.
2. Rosedale PD, Hopes R, Digby NJW, et al. 1985. Epidemiological study of wastage among racehorses 1982 and 1983. *Vet Rec* 116:66–69.
3. USDA. 2000. Lameness and laminitis in U.S. horses. Fort Collins, CO: USDA:APHIA:VS, CEAH, National Animal Health Monitoring System; 34 p.
4. McIlwraith CW, Frisbie DD, Kawcak CE, et al. 2009. Recommendation of criteria for the evaluation of macroscopic and histological changes occurring in equine osteoarthritis. *Osteoarthritis Cartilage* (in press).
5. Frisbie DD, Al-Sobayil F, Billingham RC, et al. 2008. Changes in synovial fluid and serum biomarkers with exercise and early osteoarthritis in horses. *Osteoarthritis Cartilage* 16:1196–1204.
6. Frisbie DD. 2005. Future directions in treatment of joint disease in horses. *Vet Clin North Am Equine Pract* 21:713–724.
7. Frisbie DD, Hague BA, Kisiday JD. 2007. Stem cells as a treatment for osteoarthritis. Presented at American College of Veterinary Surgeons Veterinary Symposium, Chicago, IL [available in digital format from the corresponding author].
8. Murphy JM, Fink DJ, Hunziker EB, et al. 2003. Stem cell therapy in a caprine model of osteoarthritis. *Arthritis Rheum* 48:3464–3474.
9. Augello A, Tasso R, Negrini SM, et al. 2007. Cell therapy using allogeneic bone marrow mesenchymal stem cells prevents tissue damage in collagen-induced arthritis. *Arthritis Rheum* 56:1175–1186.

10. Black LL, Gaynor J, Gahring D, et al. 2007. Effect of adipose-derived mesenchymal stem and regenerative cells on lameness in dogs with chronic osteoarthritis of the coxofemoral joints: a randomized, double-blinded, multicenter, controlled trial. *Vet Ther* 8:272–284.
11. Frisbie DD, Ghivizzani SC, Robbins PD, et al. 2002. Treatment of experimental equine osteoarthritis by in vivo delivery of the equine interleukin-1 receptor antagonist gene. *Gene Ther* 9:12–20.
12. Kisiday JD, Kopesky PW, Evans CH, et al. 2008. Evaluation of adult equine bone marrow- and adipose-derived progenitor cell chondrogenesis in hydrogel cultures. *J Orthop Res* 26:322–331.
13. Anonymous. 1991. Definition and classification of lameness. In: *Guide for veterinary service and judging of equestrian events*. Lexington, KY: AAEP; p 19.
14. Farndale RW, Buttle DJ, Barrett AJ. 1986. Improved quantitation and discrimination of sulphated glycosaminoglycans by use of dimethylmethylene blue. *Biochem Biophys Acta* 883:173–177.
15. Vick MM, Adams AA, Murphy BA, et al. 2007. Relationships among inflammatory cytokines, obesity, and insulin sensitivity in the horse *J Anim Sci*. 85:1144–1155.
16. McFarlane D, Holbrook TC. 2008. Cytokine dysregulation in aged horses and horses with pituitary pars intermedia dysfunction. *J Vet Intern Med* 22:436–442.
17. Anonymous. 2006. The GLIMMIX Procedure. Cary, NC: SAS Institute Inc; 943 p.
18. May SA, Hooke RE. 1987. The identity of the E-series prostaglandins produced by chondrocytes and synovial cells in response to a variety of stimuli. *Proc Br Equine Vet Assoc* 26:79.
19. May SA, Hooke RE, Lees P. 1989. Identity of the E-series prostaglandin produced by equine chondrocytes and synovial cells in response to a variety of stimuli. *Res Vet Sci* 46:54–57.
20. May SA, Hooke RE, Lees P. 1991. Adverse conditions in vitro stimulate chondrocytes to produce prostaglandin E2 and stomelysin. *Equine Vet J* 23:380–382.
21. May SA, Hooke RE, Lees P. 1992. Inhibition of interleukin-1 activity by equine synovial fluid. *Equine Vet J* 24:99–102.
22. Frisbie DD, Kawcak CE, Trotter GW, et al. 1998. The effects of 6-alpha methylprednisolone acetate on an in vivo equine osteochondral fragment exercise model. *Am J Vet Res* 12:1619–1628.
23. Frisbie DD, Kawcak CE, Trotter GW, et al. 1997. The effects of triamcinolone acetate on an in vivo equine osteochondral fragment exercise model. *Equine Vet J* 29:349–359.
24. Frisbie DD, Kawcak CE, Werpy NM, et al. 2007. Clinical, biochemical and histologic effects of intra-articular administration of autologous conditioned serum in horses with experimentally induced osteoarthritis. *Am J Vet Res* 68:290–296.
25. Barry FP. 2003. Mesenchymal stem cell therapy in joint disease. *Novartis Found Symp* 249:86–96; discussion –102, 70–74, 239–241.
26. Im GI, Shin YW, Lee KB. 2005. Do adipose tissue-derived mesenchymal stem cells have the same osteogenic and chondrogenic potential as bone marrow-derived cells? *Osteoarthritis Cartilage* 13:845–853.
27. Hennig T, Lorenz H, Thiel A, et al. 2007. Reduced chondrogenic potential of adipose tissue derived stromal cells correlates with an altered TGFbeta receptor and BMP profile and is overcome by BMP-6. *J Cell Physiol* 211:682–691.
28. Liu TM, Martina M, Hutmacher DW, et al. 2007. Identification of common pathways mediating differentiation of bone marrow- and adipose tissue-derived human mesenchymal stem cells into three mesenchymal lineages. *Stem Cells* 25:750–760.
29. Noel D, Caton D, Roche S, et al. 2008. Cell specific differences between human adipose-derived and mesenchymal-stromal cells despite similar differentiation potentials. *Exp Cell Res* 314:1575–1584.